LenteraBio
Berkala Ilmiah Biologi

LenteraBio, 2026; Volume 15, Issue 3: 246-252

p-ISSN: 2252-3979 e-ISSN: 2685-7871
https://journal.unesa.ac.id/index.php/lenterabio/index

Effect of Tamarind Leaf Ethanol Extract (*Tamarindus indica* L.) on Liver of White Rats (*Rattus Norvegicus*) Induced with Used Cooking Oil

Syukriah[1*], Eka Fariza Fatharani[1], Siti Amira[1]
[1]Department of Biology, Faculty of Sains and Technology, Universitas Islam Negeri Sumatera Utara Medan
*Corresponding Author, e-mail: syukriah@uinsu.ac.id

Article History:
Received:
5-December-2025
Revised:
12-April-2026
Available online:
30-September-2026
Published regularly:
30-September-2026

Abstract
Continuous consumption of used cooking oil causes damage in the liver due to free radicals. Free radicals can be counteracted by natural antioxidants derived from plants. Tamarind leaf (*Tamarindus indica* L.) is a plant that contains high amounts of antioxidants. The purpose of this study was to determine the effect of ethanol extract of tamarind leaves on liver induced by cooking oil, based on SGOT (Serum Glutamic Oxaloacetic Transaminase) levels, SGPT (Serum Glutamic Pyruvic Transaminase) levels, and histology. This study used a completely randomized design with 25 rats divided into 5 groups and 5 replications. Untreated control (UC) was not given any treatment, positive control (PC) was given used cooking oil, and while treatment groups (T1 to T3), were given tamarind leaf extract at various dose after induction. All interventions lasted for 28 days. Data were analyzed using one-way ANOVA and post hoc Duncan's test. The results showed that levels of SGOT and SGPT decreased significantly (p=0.000) and extract had an effect on minimizing liver histologic damage (p=0.000). The most optimal ethanol extract of tamarind leaves to reduce levels of SGOT and SGPT and minimize histological damage is at a dose of 250 mg/kg BW.

Keywords: cooking oil; liver health; histology; SGOT; SGPT; *Tamarindus indica*

How to Cite: Syukriah S, Fatharani EK & Amira S, 2026. Effect of tamarind leaf ethanol extract (*Tamarindus indica* L.) on white tat's liver (*Rattus Norvegicus*) induced by used cooking oil. LenteraBio; 15(3): 246-252.

DOI: https://doi.org/10.26740/lenterabio.v15p246-252

INTRODUCTION

Frying is a method of processing food that generally uses oil derived from vegetable ingredients such as coconuts, nuts, and seeds (Shastry et al., 2011). It is subsequently purified into staples including the processes of degumming, neutralization, and deodorization (Putri et al., 2021; Rengga, 2020). Cooking oil can make dishes drier, crisper, and more durable (Aisyah et al., 2014). Cooking oil heated until it reaches a high temperature frequently causes changes in its composition (Aisyah et al., 2015). Cooking oil is considered excellent if it contains more unsaturated fatty acids than saturated fatty acids. (Raharjo, 2015). The quality standard for cooking oil specifies that it must have a normal odor and color, a moisture content of ≤0.15%, an acid number ≤0.6 mg KOH/g, and a peroxide value ≤10 meq O_2/kg (SNI, 2013).

According to the Index Mundi (2021), Indonesia has the highest oil consumption for cooking in the world, with 15.4 million tons consumed in 2021, followed by India and China. There is an imbalance between consumption levels and cooking oil prices, which are too high, particularly for lower-middle-class homes and small dealers (Astari and Hanriko, 2020). That cooking oil is often reused, resulting in changes in the composition and color (becoming blacker) (Nurdyansyah et al., 2021). This cooking oil used repeatedly is known as used cooking oil that is continuously used, altering its composition, quality, and physical condition (Pangalela et al., 2020; Josephine et al., 2020)

People still eat cooking oil that has been used before, even though it has lots of harmful things in it, like LDL (low-density lipoprotein), TG (triglycerides), cholesterol, phospholipids, fatty acids, and free radicals (cyclic monomers and peroxide groups) that form when unsaturated fatty acids oxidize (Mustikasari et al., 2019; Budinastiti and Widiastiti, 2018). These toxic contents injure numerous organs in the body, including the liver (Muhartono et al., 2018).

The liver is an organ that has an important role in the metabolic process, storage of various substances, and detoxification of toxins (Jane et al., 2019). Liver tissue consists of liver cells (hepatocytes), portal ducts (portal veins), and sinusoids (Astari and Hanriko, 2020). The liver converts

OPEN ACCESS CC BY NC

harmful substances that enter the body into substances that are safe for the body through the biotransformation process. This causes the liver to be easily exposed to damage, both in terms of organ function and structure (Aisyah et al., 2015). Liver damage is characterized by increased levels of SGOT (Serum Glutamic-Oxaloacetic Transaminase) and SGPT (Serum Glutamic Pyruvic Transaminase) in the serum (Odeghe and Asagba, 2012), swelling of the anatomical structure of the liver, and necrosis in its constituent cells (Nurdyansyah et al., 2021).

Used cooking oil contains xenobiotic components; if consumed, it produces high levels of free radicals caused by the destruction of oil molecules as a result of the heating process repeatedly, resulting in oxidative stress in cells. Oxidative stress is a condition of imbalance between pro-oxidants and antioxidants, resulting in an excess of pro-oxidants in the tissue. Without additional antioxidants, such as bioactive plant components, oxidative stress can cause cell damage. Continuous oxidative stress affects the response of liver cells, leading to pathological conditions. When free radical exposure is chronic, irreversible cell damage such as degeneration and necrosis can occur. Liver cell degeneration is a reversible form of liver damage, characterized by swelling and fatty liver cells. Histologically, degeneration is characterized by hepatocyte swelling, granular cytoplasm, and cells that appear somewhat cloudy. Reversible damage is also seen in hepatocyte swelling. Necrosis is irreversible liver cell damage. Necrotic damage usually follows degenerative damage. Histologically, necrosis is characterized by liver cells that appear to disappear due to cell rupture, usually leaving only connective tissue shadows and fragments of cell nuclei (Ersa et al., 2024; Hadjipor, 2011; Astari and Hanriko, 2020).

Antioxidants are chemicals that can block oxidation by scavenging free radicals, making them highly reactive molecules (Tunny, 2020). Antioxidants operate as oxidation inhibitors, reacting with reactive free radicals to create relatively stable, non-reactive free radicals that can protect cells from the harmful effects of reactive oxygen free radicals. Antioxidants' efficiency is proportional to the oxidative power of other compounds (Khaira, 2010). Antioxidants include vitamins C and E, as well as secondary metabolite chemicals such as flavonoids (Santoso, 2021). Antioxidants are present in a variety of natural components (Irianti, 2021), one of which is in tamarind leaves.

Tamarind leaves (*Tamarindus indica*) have a variety of uses, including traditional medicine, food, fuel, and other necessities (Silalahi, 2020). Megaswati et al., (2021) reported that tamarind leaves have excellent antioxidant activity and contain secondary metabolites such as alkaloids, saponins, polyphenols, tannins, and flavonoids. The use of tamarind leaves is an attempt to empower ubiquitous plants that are suggested by the WHO (World Health Organization) (2010) for use as herbal medicine to improve health conditions. Previous research showed that tamarind leaves can cure liver tissue damage (Ghoneim and Eldahshan, 2012). Based on the aforementioned description, this study investigated the antioxidant effect of tamarind leaves on liver organs subjected to free radical exposure from used cooking oil, both in terms of liver function and histological appearance.

MATERIALS AND METHODS

This experimental study used a Completely Randomized Design using 25 male white rats (*Rattus novergicus* L.) divided into 5 groups; including untreated control (UC), positive control (PC), treatment 1, 2, and 3 (T1, T2, and T3, respectively). NC group was fed standard feed (pellets) and 1% CMC (Carboxymethyl Cellulose); the PC group was exposed to 1.5 mL of used cooking oil; and the T1, T2, and T3 groups were exposed to 1.5 mL of used cooking oil and treated with 1% CMC and tamarind leaf extract (*Tamarindus indica* L.) at a dose of 150 mg/kg BW, 200 mg/kg BW, and 250 mg/kg BW, respectively. The interventions lasted for 28 days after aacclimatization for 7 days.

A total of 8 kilograms of good-quality tamarind leaves (*Tamarindus indica* L.) were collected from HM Said Street in Medan Perjuangan District. About 8000 grams of tamarind leaves were thoroughly washed and sun-dried with a black cloth covering the leaves. The dried leaves were crushed using a blender and then sieved to produce powder. The powder was macerated with 96% ethanol in a container with a tight lid for 48 hours and stirred occasionally. The maceration results were then filtered to separate the filtrate and further processed using rotary evaporator to yield thicker extract.

Measurement of SGPT and SGOT levels was carried out by taking blood from mice through the orbital sinus by scratching a hematocrit pipette on the orbital sinus under the eyeball towards the optic foramen, and the dripping blood was collected with a blood tube. Blood sampling was carried out on the 28th day. SGOT and SGPT levels were determined using the kinetic-IFCC (International Federation of Clinical Chemistry) method.

The liver was dissected from rat and placed in a Neutral Buffer Formalin 10% fixative solution for three days. The liver was then cut into thick sections and placed into labeled tissue cassettes before dehydrated in graded alcohol. Tissue sample was then embedded in paraffin and cut into using a microtome at 4-5 µm thickness. Sections were stained using hematoxylin-eosin method and covered with a coverslip. Liver histopathology was evaluated were based on Aisyah (2015), with the following damage level criteria: level 0 indicated no cell degeneration/necrosis (normal), level 1 indicated by 1-10 cell degeneration/necrosis (mild); level 2 indicated by 11-20 cell degeneration/necrosis (moderate); level 3 indicated by >20 cell degeneration/necrosis (severe). Cell degeneration was defined by fat accumulation that causes cells to swell, characterized by hepatocyte swelling, clumped filamentous tissue, hepatocyte vacuolation, mitochondrial swelling, and cell membrane blebbing (Ersa et al., 2024). Necrosis, on the other hand, was defined by cell damage characterized by rupture of the plasma membrane (Lovitasari et al., 2021).

The data obtained included SGPT levels, SGOT levels, and degeneration and necrosis, which were statistically processed using SPSS 29. The analysis used was the homogeneity test (Bartlett's test). If the data were found to be homogeneously distributed, one-way analysis of variance (ANOVA) was performed at a $P<0.05$ level. If significant differences were found, Duncan's test was used.

RESULT

Used cooking oil testing was carried out to determine the quality of the used cooking oil that was administered to the experimental animals. The used cooking oil used in this study was previously pure palm oil which had been used to fry potatoes, sweet potatoes, and tofu regularly. Heating cooking oil at high temperatures and repeatedly can also change the fat configuration from cis-isomer fatty acids to trans isomer fatty acids, peroxides, and free radical components that can increase the risk of malignancy (Josephine, 2020). The utilized cooking oil test results were compared to the Indonesian National Standard (SNI) of cooking oil usage criteria. According to SNI (2013), the oil quality standards for moisture content test parameters could not exceed 0.15%; the acid number could not exceed 0.6 mg KOH/g, and the peroxide number could not exceed 10 mEq O_2/kg. The results of the used cooking oil test showed that water content and free fatty acids are consistent with the SNI standard; the peroxide number is not. The used cooking oil contains a moisture content of 0.0698%, a free fatty acid content of 0.1912%, and a peroxide value of 16.99.

The one-way ANOVA test revealed a significant effect of tamarind leaf ethanol extract on the SGOT and SGPT levels of the liver induced by used cooking oil (ANOVA test, $p<0.05$). Duncan post hoc test showed difference between positive and negative control, indicating used cooking oil was able to increase SGOT and SGPT level (Table 1). The optimum dose of extract for reducing SGOT and SGPT levels in rats induced by used cooking oil is 250 mg/kg BW, where the SGOT and SGPT levels tend to be closer to the SGOT and SGPT levels in the negative control group.

Table 1. SGOT and SGPT level of examined group

Group	SGPT values (U/L)	SGOT values (U/L)
UC	28.20 ± 5.17^{a}	65.00 ± 16.19^{a}
PC	328.80 ± 18.20^{e}	256.52 ± 20.52^{e}
T1	196.40 ± 20.89^{d}	179.60 ± 11.59^{d}
T2	136.20 ± 10.03^{c}	148.80 ± 6.19^{c}
T3	48.40 ± 6.47^{b}	94.40 ± 11.14^{b}

Remarks: UC: Untreated control, PC: positive control, T1: extract dose 150mg/kg BW, T2: extract dose 200mg/kg BW, T3: extract dose 250mg/kg BW. Different superscript letters indicated significant difference ($p<0.05$).

Liver histology showed reduced damage after tamarind leaf extract treatment at various dose. Higher dose of extract had lower liver damage. In this study, tamarind leaf ethanol extract was not able to restore hepatocytes to normal level, but tamarind leaf ethanol extract still showed an effect in the form of a reduction in the amount of liver cell damage caused by used cooking oil (Figure 1).

Data analysis on the level of liver tissue damage showed significant level ($p = 0.000$), meaning that the administration of tamarind leaf ethanol extract affected liver cell degeneration and necrosis in cooking oil-induced rats ($p <0.05$). Significant difference was also found between positive and negative control groups (Table 2). Data analysis showed significant improvement of tamarind leaf extract on the degeneration and necrosis induced by used cooking oil ($p<0.05$), compared to the control group.

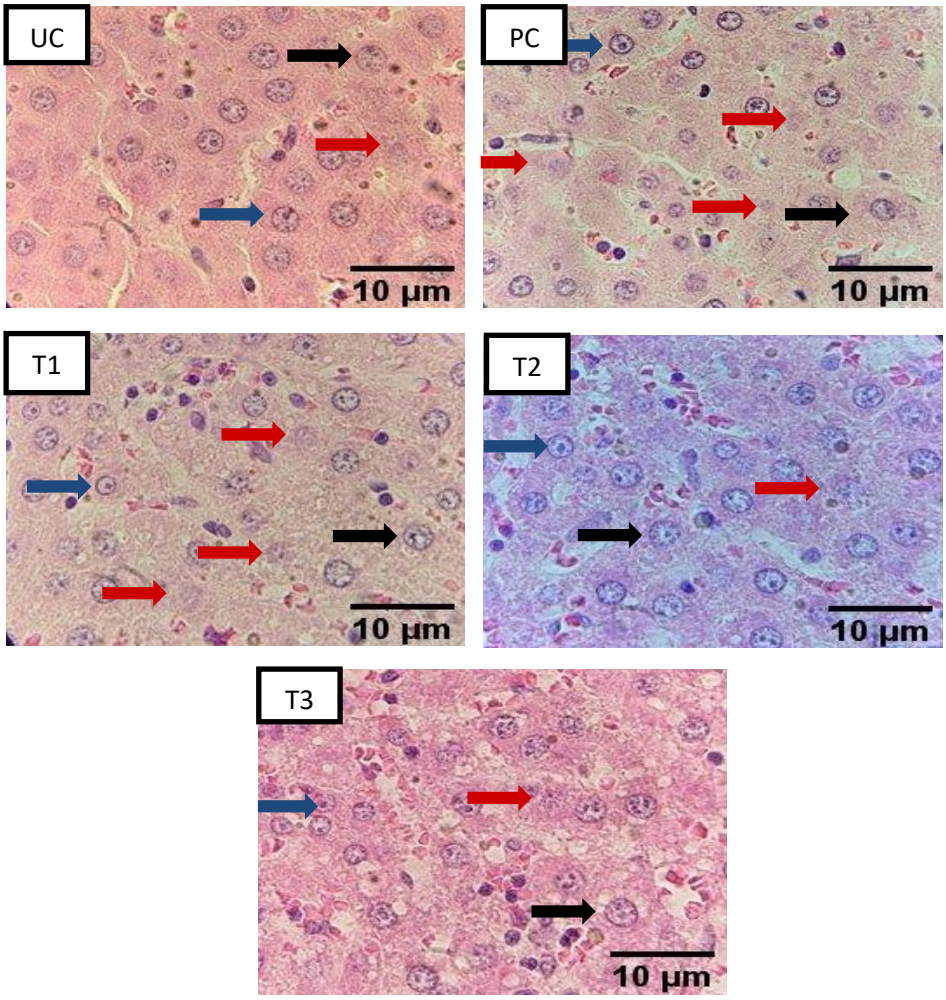

Figure 1. Liver sections after the administration of induction of used cooking oil and tamarind leaf ethanol extract. UC: untreated control, PC: positive control, T1: extract dose 150mg/kg BW, T2: extract dose 200mg/kg BW, T3: extract dose 250mg/kg BW. Blue (normal hepatocytes with polygonal shape, rich eosinophilic cytoplasm, and round or oval nucleus), red (necrosis in the form of a darkened and shrunken nucleus or karyorrhexis (nuclear fragmentation), and cytoplasm that appears pale and eosinophilic), black (degeneration is characterized by swelling of hepatocyte cells and turbidity of the cytoplasm due to protein strengthening).

Table 2. Liver degeneration and necrosis in examined groups

Group	Degeneration	Necrosis	Level
UC	1.60 ± 0.55^{a}	2.40 ± 0.54^{a}	1
PC	31.40 ± 2.7^{e}	31.40 ± 2.60^{e}	3
T1	23.80 ± 0.83^{d}	24.20 ± 1.64^{d}	3
T2	15.40 ± 1.51^{c}	14.80 ± 1.30^{c}	2
T3	8.20 ± 0.83^{b}	8.60 ± 1.14^{b}	1

Remarks: UC: untreated control, PC: positive control, T1: extract dose 150mg/kg BW, T2: extract dose 200mg/kg BW, T3: extract dose 250mg/kg BW. Different superscript letters indicate statistical difference ($p<0.05$)

DISCUSSION

The high number of peroxides is induced by repeated frying, which causes thermal oxidation and increases peroxide levels. Thermal oxidation is the process of forming peroxides through heating and exposure to air (Yuarini et al., 2018). The high peroxide level in used cooking oil is considered harmful since it can produce free radicals that are carcinogenic in the body. Free radicals with unpaired electrons will bind their electron pairs from other chemicals, making this substance highly reactive in harming biological tissues (Aisyah et al., 2015). According to Mulasari et al. (2012), cooking oil with high peroxide content displays organoleptic characteristics such as brownish, hazy, precipitated, frothy, and rotten odors. This is consistent with the characteristics of the utilized cooking oil examined in this investigation. The water content, fatty acid value, and peroxide value of used cooking oil in this test

exceed the standard quality of cooking oil, namely, the water content does not exceed 0.15%, the fatty acid value does not exceed 0.6 mg KOH/g, and the peroxide value does not exceed 10 meq O2/kg. Used cooking oil that is high in peroxide can increase SGPT and SGOT levels in the blood.

Used cooking oil is high in peroxide and is harmful to the health of body tissues. This is proven by the results of the study by Oeji et al. (2007), in which the administration of used cooking oil to the treatment group induced by cooking oil heated 4 times, 10 times, 20 times, and 40 times had a significant impact on the number of necrotic hepatocytes compared to the group induced by used cooking oil without heating.

The results of this study showed that the SGPT levels in the positive group were 11 times higher than the SGPT levels in the untreated group, where the SGPT levels of normal mice were 47,44 U/liter (Nofita et al., 2020) and the SGOT levels of mice in the positive control group were almost 4 times higher than the untreated control where the SGOT levels of normal mice were 45.7-80.8 U/liter (Krysanti and Widjanarko, 2014). This indicates liver damage at the chemical examination stage. SGPT (Serum glutamic pyruvic transaminase) or ALT (Alanine aminotransferase) is an enzyme found only in the liver. In cases of minor liver cell damage, the SGPT enzyme can leak into the bloodstream; therefore, blood levels of SGPT can be used as an indicator of liver damage, even at low levels. This allows SGPT to provide useful information on the severity of liver function abnormalities. SGPT activity in the liver can be identified at very low levels (Kahar, 2018). The normal value of the SGPT enzyme in human blood ranges from 14-35 U/L. Meanwhile, SGOT (serum glutamic oxaloacetic transaminase), also known as AST (aspartate aminotransferase), is an enzyme that catalyzes the reversible transfer of the amino groups between aspartate and ketoglutarate into glutamate and oxaloacetate. SGOT helps hepatocyte cells function in the liver (Hasni and Darwis, 2018). When the liver is damaged, SGOT is released into the bloodstream. and the higher the level of SGOT in the blood, the more damage the liver suffers. Therefore, SGOT, which is present in organs other than the liver, does not specifically indicate liver damage. Normal levels of SGOT in the blood are in the range of 6-33 U/L in men and 10-25 U/L in women (Chairini and Widodo, 2020).

These two enzymes are transaminase enzymes with the same function: to aid in the process of protein and fat synthesis in liver cells. However, while acting as biocatalysts, the catalysis method that these two enzymes use to initiate the synthesis of lipids and proteins is distinct. SGOT catalyzes the transfer of amino groups from L-aspartate to ketoglutarate, whereas SGPT catalyzes the transfer of amino groups from L-alanine to ketoglutarate (Nasution et al., 2015). Furthermore, SGOT is located in the mitochondria of hepatocyte cells, whereas SGPT is found in the cytoplasm (Widyastuti et al., 2018). Increase of SGOT and SGPT levels due to high peroxides in used cooking oil. Peroxides are metabolized by the cytochrome P450 enzyme in the liver into free radicals. These free radicals will then bind to hepatocyte cells and increase the permeability of the cell membrane, which will cause inflammation or damage to liver cells (Wahyudi et al., 2018).

Table 1 also showed that the liver's SGOT and SGPT levels differed considerably between the untreated control and treatment groups. In groups given leaf extract, the level of SGOT and SGPT were lower. Higher level of extract resulted in lower SGOT and SGPT level. According to results, the most effective dose of tamarind leaf ethanol extract to lower SGOT and SGPT level was 250 mg/kg BW.

Lower level of SGOT and SGPT consistent with the improvement of liver tissue due to by leaf extract administration. Antioxidants from extract bound to free radicals from cooking oil, resulted in lower cell damage. Decreased damage on liver tissue reduced the level of SGOT and SGPT level in the blood. Similarly, Ghoneim and Eldahshan (2011), found that antioxidant content in tamarind leaves can treat damage to liver function and liver tissue.

Liver cell degeneration is a reversible liver disease that is distinguished by swelling and fatty liver cells. Histologically, degeneration is characterized by hepatocyte enlargement, granular cytoplasm, and hazy cells. Degeneration is frequently caused by hazardous stimuli (Ressang, 1984). Liver cell degeneration is also regarded as a minor liver injury, in which the injury affects cell structures such as mitochondria and cytoplasm, interfering with the cell metabolism process. However it can progressed into cell death, resulting in irreversible damage (Nazarudin et al., 2017).

Meanwhile, necrosis causes irreparable harm to liver cells. Necrosis damage typically follows degenerative damage. Histologically, necrosis resembles liver cells that appear to disappear as a result of cell rupture, leaving only a shadow of connective tissue and cell nucleus fragments (Hadjipor, 2011). Liver necrosis is considered to be the result of the interaction between free radicals from metabolism and biomolecules that make up the liver cell membrane (Nazarudin et al., 2017). Maulana and Ulilalbab

(2014) research states that induction of used cooking oil can cause necrosis in liver cells. In this study, the induction of used cooking oil was carried out for 4 consecutive weeks with a dose of 1 ml.

Based on Table 2, it can also be seen that the untreated group and the positive control group were significantly different from treatment group 1 (150 mg/kg BW), treatment group 2 (200 mg/kg BW), and treatment group 3 (250 mg/kg BW). This shows that the ethanol extract of tamarind leaves affects the repair of liver cell damage in the form of necrosis and liver cell degeneration caused by used cooking oil. The higher the dose given, the lower the value of liver cell damage in treatment groups 1, 2, and 3, and the value returned to normal. Based on the test results, the most effective dose of ethanol extract of tamarind leaves to minimize the rate of degenerative damage and necrosis in liver cells was in treatment group 3 at a level of 250 mg/kg BW.

Liver cell damage could be minimized by tamarind leaf ethanol extract, as evidenced by a decrease in the level of damage in each treatment group (Table 3). This can happen because of the antioxidant content contained in the tamarind leaf ethanol extract that is given. Antioxidants are chemicals that inhibit the oxidation of free radicals during lipid oxidation. Antioxidants work by providing one electron to oxidative substances, inhibiting their action (Dwimayansari, 2018). Antioxidants scavenging free radicals induced by spent cooking oil in liver cells lower the oxidative via electron transfer (Astari and Hanriko, 2020). In this study, antioxidants in tamarind leaf ethanol extract are not used as a trigger for liver cell regeneration, but rather as a substance that can prevent triggers for liver cell damage, hence minimizing damage.

CONCLUSION

The administration of tamarind leaf extract (*Tamarindus indic*a L.) affects the minimization of SGPT and SGOT levels and histological damage to rat livers, including necrosis and degeneration induced by used cooking oil, with an optimum dose of 250 mg/kg BW.

ACKNOWLEDGEMENTS

The author would like to thank the Biology study program, State Islamic University of North Sumatra Medan, for facilitating the testing laboratory in this study.

CONFLICT OF INTEREST

The authors declare there is no conflict of interest in this article.

REFERENCES

Aisyah S, Balqis U, and Friyan Ek, 2014. Histopatologi jantung tikus putih (*Rattus norvegicus*) akibat pemberian minyak jelantah. *Jurnal Medika Veterinaria 8*(1): 87–90.

Aisyah S, Budiman HGDFB, Aliza D, Salim MN, Balqis U, and Armansyah T, 2015. Efek pemberian minyak jelantah terhadap gambaran histopatologis hati tikus putih (*Rattus norvegicus*). *Jurnal Medika Veterinaria 9*(1): 26-29.

Astari PDS and Hanriko R, 2020. Black garlic (*Allium sativum*) sebagai terapi adjuvan potensial pada kerusakan hepar yang diinduksi minyak jelantah. *Majority 9*(1): 1–6.

Budinastiti R, Sunoko HR and Widiastiti NS, 2018. The effect of cloud ear fungus (*Auricularia polytricha*) on Serum total cholesterol, LDL and HDL levels on wistar rats induced by reused cooking oil. *E3S Web of Conferences 31(*06006): 1-5.

Chairini S and Widodo, 2020. Profile of SGOT and SGPT levels in patients with pulmonary tuberculosis. *Jurnal Laboratorium Medis 2*(1): 18-21.

Dwimayansari R, 2018. Rumput laut: antioksidan alami penangkal radikal bebas. *Oseana XLIII*(2): 13–23.

Ersa RC, Susianti, Kurniawaty E and Mustofa S, 2024. Pengaruh pemberian minyak jelantah 1,5 ml/hari selama 14 hari terhadap histopatologi hepar rattus norvegicus jantan. *Medula 14*(5): 901-906.

Ghoneim AI and Eldahshan OA, 2011. Anti-apoptotic effects of tamarind leaves against ethanol-induced rat liver injury. *Journal of Pharmacy and Pharmacology 64*: 430–438.

Hadjipor N, 2011. Histopatological comparison of gentamicin and amikacin nephrotoxicity in rabbits. *Journal of Animal and Veterinary Advances 10*(8).

Hasni SJ and Darwis I, 2018. Gambaran hasil pemeriksaan SGOT dan SGPT pada penghirup lem di Jalan Abdul Kadir kota Makassar. *Jurnal Media Laboran;* 8(2): 43–4

Index Mundi, 2021. 10 negara konsumen minyak sawit terbesar, Indonesia juaranya. *katadata.co.id.* Accessed on 6 April 2025.

Irianti T, 2021. *Antioksidan dan Kesehatan*. Yogyakarta: Gadjah Mada University Press.

Jane MN, Appolos OG and Debora OO, 2019. Effects of vegetable oil reused for frying on the liver of albino rats.

Science Journal of Chemistry 7(1): 11–14
Josephine J, Candra A and Rahadiyanti A, 2020. Efek ekstrak tomat terhadap enzim katalase hepar tikus wistar yang terpapar minyak jelantah. *Journal of Nutrition and Health 8*(1): 1–11.
Kahar H, 2018. Pengaruh hemolisis terhadap kadar serum glutamate pyruvate transaminase (SGPT) sebagai salah satu parameter. *The Journal of Muhammadiyah Medical Laboratory Technologist 1*(1): 38–46.
Khaira K, 2010. Menangkal radikal bebas dengan anti-oksidan. *Jurnal Sainstek 11*(2): 183–187.
Krysanti A and Widjanarko SB, 2014. Subacute toxicity testing of glucomannan (*A . muelleri Blume*) toward SGOT and sodium of wistar rats by in vivo. *Jurnal Pangan dan Agroindustri 2*(1): 1–6.
Lovitasari, Mulyanto A and Dhanti KR, 2021. Pengaruh kopi instan tinggi gula dosis bertingkat terhadap gambaran histologi hepar tikus putih *Rattus norvegicus* galur wistar. *Bioma 6*(2): 23-30.
Maulana HI, Ulilalbab A, Anugerah DP and Estiasih T, 2014. Effervescent rosela ungu mencegah penurunan nilai sod dan mencegah nekrosis hepar pada tikus wistar yang diberi minyak jelantah. *Jurnal Kedokteran Brawijaya* (8): 85–90.
Megaswati, Sukmawati and Aminah, 2021. Uji aktivitas antioksidan fraksi etil asetat daun asam jawa (*Tamarindus indica* L .). *Wal'afiat Hospitas Journal 2*(2): 95–102.
Muhartono, Yudistira MA, Putri NT and Oktafany, 2018. Minyak jelantah menyebabkan kerusakan pada arteri koronaria, miokardium, dan hepar tikus putih (*Rattus norvegicus*) jantan galur sprague-dawley. *Jurnal Kedokteran Unila 2*(2): 129–135.
Mulasari SA and Utami RR, 2012. Kandungan peroksida pada minyak goreng di pedagang makanan gorengan sepanjang jalan Prof. Dr. Soepomo umbulharjo yogyakarta tahun 2012. *Archive of Community Health 1*(2): 120–123.
Mustikasari I, Saktini F and Gumay AR, 2019. Pengaruh frekuensi penggorengan minyak jelantah terhadap hepar tikus wistar (*Rattus norvegicus*). *Jurnal Kedokteran Diponegoro 8*(3): 1000–1010.
Nasution AY, Adi P and Santosa PA, 2015. Effect of propolis extract on SGOT (serum glutamic oxaloacetic transaminase) and SGPT (serum glutamic pyruvic transaminase) level of wistar rats (*Rattus norvegicus*) with high fat diet. *Majalah Kesehatan FKUB 2*(3): 120–126.
Nazarudin Z, Muhimmah I and Fidianingsih I, 2017. Segmentasi citra untuk menentukan skor kerusakan hati secara histologi. *Seminar Nasional Informatika Medis* (SNIMed) VIII: 15–21.
Nurdyansyah F, Widyastuti DA and Mandasari AA, 2021. Efek ekstrak etanol kulit petai (*Parkia speciosa*) terhadap fungsi hepar *Rattus norvegicus* yang terpapar minyak goreng bekas. *Jurnal Ilmu Kefarmasian Indonesia*; *19*(1): 111–117.
Odeghe OB and Asagba SO, 2012. Palm kernel oil effects on the activity of aspartate aminotransferase 1 (AST) and alanine aminotransferase (ALT) in the plasma and tissue of albino rat. *International journal of pharmacy and pharmaceutical science 4*(3): 364-266.
Oeji, Andhika A, Atmadja WL, Achmad S and Tohardi A, 2007. Gambaran anatomi mikroskopik dan kadar malondialdehida pada hati mencit setelah pemberian minyak kelapa sawit bekas menggoreng. *Jurnal Kesehatan Masyarakat 7*(1): 15-25.
Pangalela AA, Weta IW and Maker II, 2020. Astaxanthin menghambat perlemakan hati dan peningkatan kadar serum gamma-glutamyltransferase pada tikus wistar jantan yang diberi minyak jelantah. *Indonesian Journal of Clinical Nutrition Physician 3*(1): 46–55.
Putri GF, Umar LA and Yunita E, 2021. Histopatologi testis pada tikus putih (*rattus norvegicus*) yang diberikan minyak jelantah dan infusa teh hitam (*Camellia sinensis*). *Jurnal Pendidikan Biologi dan Sains 4*(1): 48–61.
Rengga W, 2020. *Perpanjangan Masa Pakai Minyak Goreng*. Penerbit Deepublish, Yogyakarta.
Ressang S, 1984. *Patologi Khusus Veteriner*. Denpasar: Percetakan Bali.
Santoso U, 2021. *Antioksidan Pangan*. Yogyakarta: Gadjah Mada University Press.
Shastry CS, Patel NA, Joshi H and Aswathanarayana BJ, 2011. Evaluation of effect of reused edible oils on vital organs of wistar rats. *Nitte University Journal of Health Science 1*(4): 10-15.
Silalahi M, 2020. Bioaktivitas asam jawa (*Tamarindus indica*) dan pemanfaatannya. *Jurnal Biologi dan Pembelajarannya 7*(2): 85–91.
SNI, 2013. Minyak Goreng. Badan Standardisasi Nasional. 3741: 2013. ICS 67.200.10.
Tunny R, Mahulauw MAH and Darmanta K, 2020. Identifikasi kandungan senyawa fitokimia dan uji aktivitas antioksidan ekstrak melalui metanol daun asam jawa kecamatan kairatu kabupaten seram bagian barat. *Tunas Riset Kesehatan 10*(1): 1-5.
Wahyudi A, Bahar Y and Septianawati P, 2018. Pengaruh ekstrak etanol daun kemangi (*Ocimum basilicum l. Folium*) terhadap kadar SGOT dan SGPT tikus putih *(Rattus norvegicus* strain wistar*)* yang diinduksi MSG. *Herb-Medicine Journal 1*(1): 30-39.
WHO (World Health Organization), 2010. WHO monographs on selected medicinal plants, *Geneva* 1: 452.
Widyastuti E, Maharani N and Utomo AW, 2018. Effect of mangosteen peel extract on SGOT and SGPT in rats fed reused cooking oil. *Jurnal Kedokteran dan Kesehatan 9*(2): 45–49.
Yuarini DAA, Putra GPG, Wrasiati LP and Wiranatha AAPAS, 2018. Karakteristik minyak goreng bekas yang dihasilkan di kota denpasar. *Media Ilmiah Teknologi Pangan 5*(1): 49–55.